

Characteristic morphology of the marginal bone resorption for different implant systems

B. Al-Nawas, A. Bähr, M. O. Klein, Th. Morbach, W. Wagner

Oral and Maxillofacial Surgery, Johannes Gutenberg-Universität Mainz, Germany

Introduction

A physiologic marginal bone reaction, which takes place mainly in the first year after insertion / loading of the implant, is known for many years. Many biological and mechanical factors have been discussed to be responsible for the physiologic marginal bone resorption. Only few studies are found, which focus on the direct clinical comparison of different implant systems in a single indication.

Hypothesis

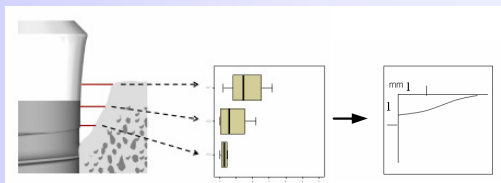
Different construction principles of the crestal part of different implant systems result in characteristic bone resorption pattern.

Patients and methods

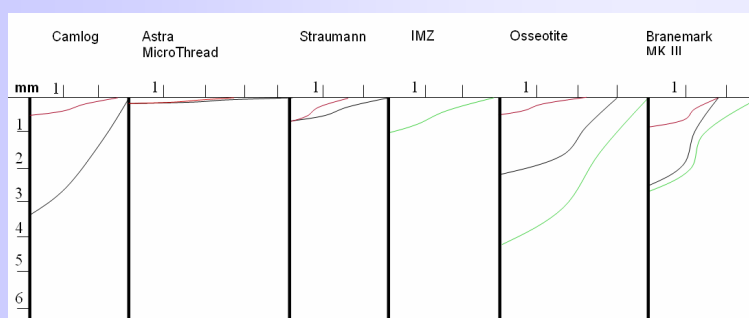
In a retrospective study using post Op and follow up panoramic radiographs the following implants were included:

- clinical loading time of 3 and 4 years.
- partial shortened arch with a fixed restoration.
- No augmentation procedures
- healthy patients without bone disease or radiation therapy.

Medial and distal values of the vertical and horizontal bone loss were measured. And adjusted for the projection bias using implant dimensions. Mean values of the medial and distal values were calculated.



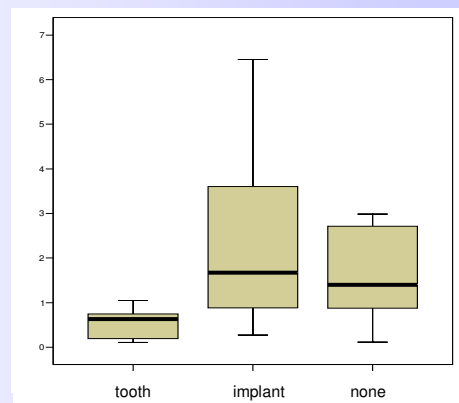
Evaluation of horizontal bone loss: The vertical bone resorption is divided into 3 equal thirds. The median resorption of the vertical and the three horizontal graphs are transferred to a graph using a mm axis.



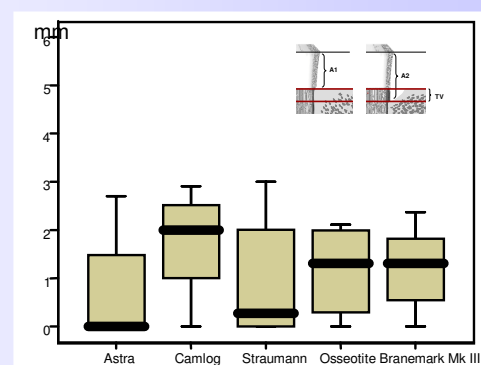
Morphology of the median vertical and horizontal bone loss. — 1-2 y — 3-4 y — 5-7y

Implant	Number
Astra MicroThread	17
Branemark MK II	12
Camlog Root Line	37
IMZ	13
Straumann Regular Neck	14
3i Osseotite	13

Number of implants



Area of bone resorption in relation to neighbor structures < 2mm



Vertical bone loss

Conclusion

Even with the restrictions of the accuracy of panoramic radiographs some characteristic differences were seen: The horizontal bone resorption was similar for all systems. Vertical bone loss for implants with a rigid (conical) implant abutment connection and those with a transgingival neck showed little bone loss resulting in a shallow bone resorption pattern. Two piece implants with a “tube in tube” internal connection and external hex implants showed a steep resorption pattern.